



# A 50-Year-Old Male with a One Week History of a "Smudge" in his Left Eye

Himanshu Banda, MD; Thomas K. Krummenacher, MD



## Introduction:

A 50-year-old male presents with a 1 week history of a "smudge" in his vision in his left eye. Other than treated hyperlipidemia, the patient denies any other known medical conditions. The patient takes a daily statin, but no other medications or supplements. He had no other associated symptoms with his visual disturbance.

## Exam:

Best corrected visual acuity was 20/20 in both eyes. No relative afferent pupillary defect was noted. Confrontation to visual field and extraocular motility was intact in both eyes. Intraocular pressure and anterior segment examination was otherwise unremarkable.

Dilated fundus examination (DFE) revealed intraretinal whitening in the macula superior to the fovea (Figure 1). Spectral-domain optical coherence tomography (SD-OCT) of the lesion indicated hyper reflectivity of the inner retinal layers (Figure 2). The outer retinal layers appeared to be normal on OCT. Fluorescein angiography (FA) of the left eye indicated a normal arm-to-retina perfusion time, with no perfusion defects (Figure 3). Optical

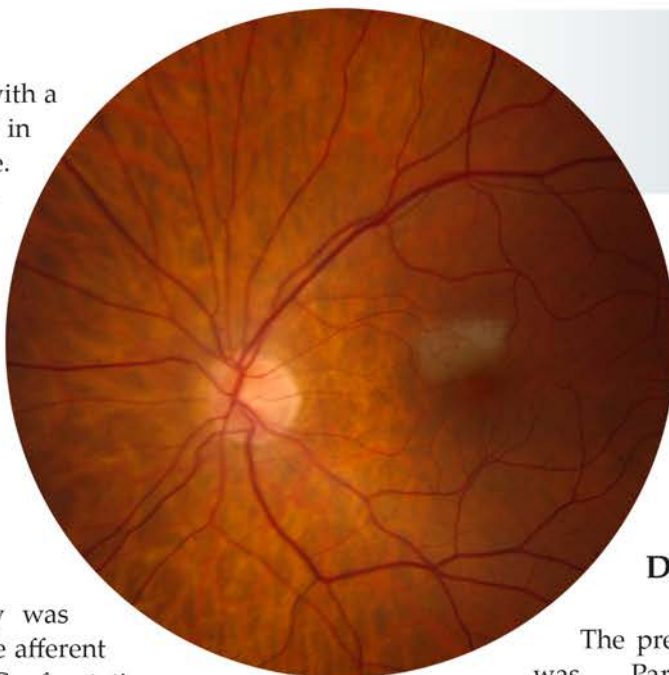


Figure 1: A fundus photo of the left eye reveals intraretinal whitening superior to the fovea.

coherence tomography angiography (OCTA) indicated possible capillary nonperfusion at the location of the lesion in the outer retinal capillary plexus (Figure 4). The fundus examination was normal in the right eye.

## Discussion:

The presumed diagnosis in this case was Paracentral Acute Middle Maculopathy (PAMM) of the left eye. PAMM was first described in 2013 by Sarraf et al as a variant of Acute Macular Neuroretinopathy (AMN)<sup>1</sup>. Though looking similar on fundus examination, the main differences are noted with SD-OCT findings; AMN tends to

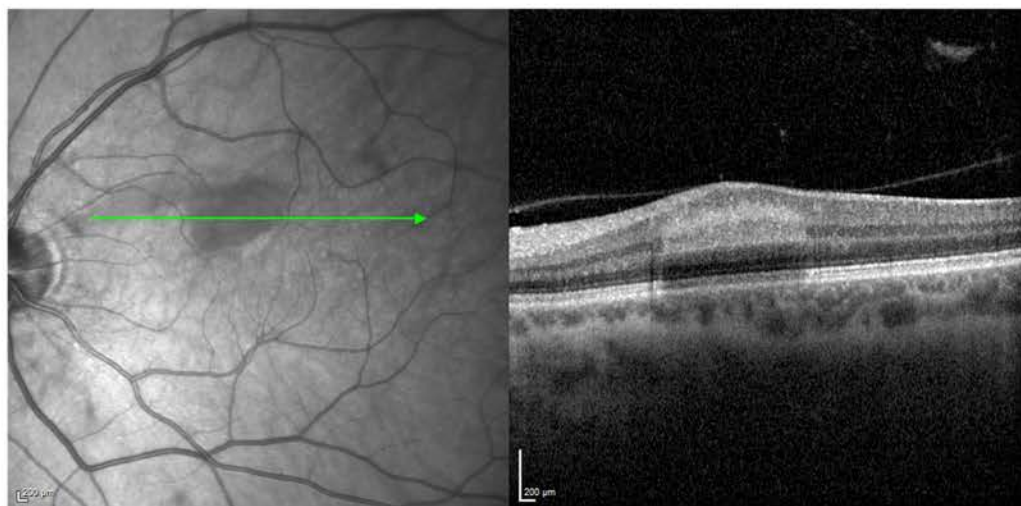


Figure 2: An OCT on the left eye indicates hyper reflectivity of the inner retinal layers.



effect the outer retinal layers, in the outer plexiform and outer nuclear layers. A worse visual prognosis may be associated with AMN given that ellipsoid zone, and even photoreceptor disruption can occur.

PAMM typically presents in the late 50's and 60's, and is often found in the setting of other retinal vascular diseases such as hypertension or diabetes. On OCT, PAMM characteristically appears as a placoid, hyperreflective band at the level of the inner nuclear layer (INL). On subsequent examinations, the INL hyperreflectivity may improve, however atrophic changes can be noted which can correspond with persistent visual disturbances<sup>2</sup>. At this time, the lack of standardized data and image quality between consecutive scans limits OCTA interpretation, however outer retinal capillary plexus

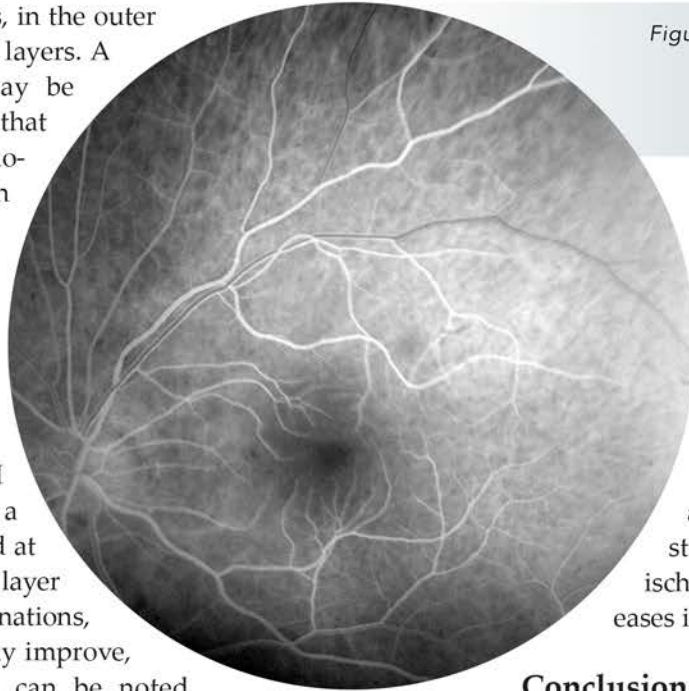


Figure 3: Fluorescein angiography of the OS indicated a normal arm-to-retina perfusion time, with no perfusion defects.

nonperfusion has been described<sup>3</sup>. SD-OCT remains the diagnostic test of choice for PAMM<sup>4</sup>.

The exact etiology of PAMM remains unknown, though there are a diverse spectrum of reported associations<sup>5,6</sup>. Evaluation and risk stratification of systemic ischemic and inflammatory diseases is recommended<sup>1</sup>.

### Conclusion:

Given our patient was healthy other than controlled hyperlipidemia, a systemic workup was recommended. Negative or normal findings included a physical

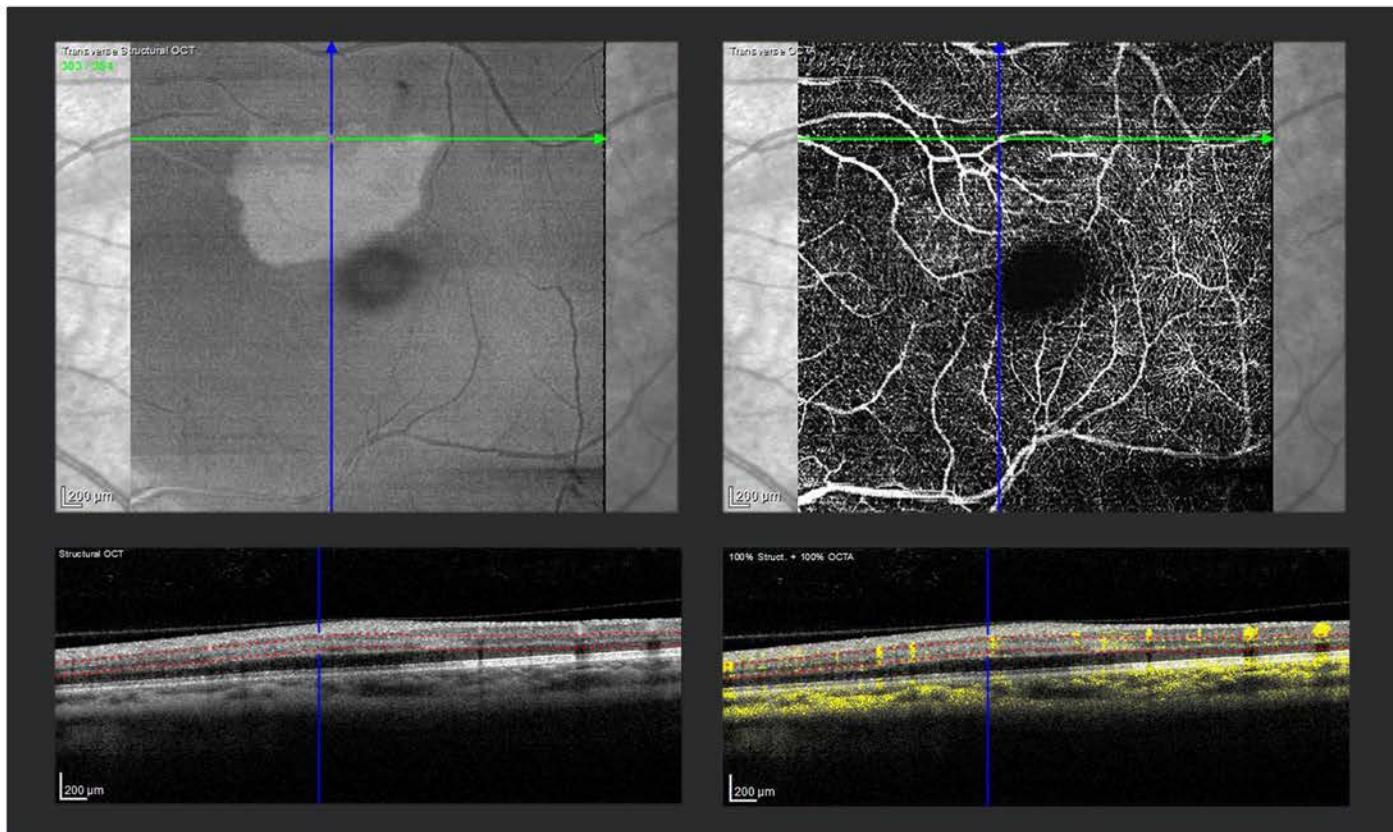


Figure 4: Optical coherence tomography angiography (OCTA) indicated possible capillary nonperfusion at the location of the lesion in the outer retinal capillary plexus .



examination by a primary care physician, blood pressure, a carotid duplex, and laboratory testing for diabetes and systemic inflammation (erythrocyte sedimentation rate, c-reactive protein). In addition to his statin, the patient is placed on a daily aspirin.

Two-week follow up, the patient noted improvement in his scotoma. Repeat dilated fundus examination revealed near resolution of retinal whitening (Figure 5) and hyper-reflectivity of middle retinal layers.

**References:**

1. Sarraf D, Rahimy E, Fawzi AA, et al. Paracentral acute middle maculopathy: a new variant of acute macular neuroretinopathy associated with retinal capillary ischemia. *JAMA Ophthalmol* 2013;131:1275-87.
2. Chen X, Rahimy E, Sergott RC, et al. Spectrum of Retinal Vascular Diseases Associated With Paracentral Acute Middle Maculopathy. *Am J Ophthalmol* 2015;160:26-34 e1.
3. Pecen PE, Smith AG, Ehlers JP. Optical Coherence Tomography Angiography of Acute Macular Neuroretinopathy and Paracentral Acute Middle Maculopathy. *JAMA Ophthalmol* 2015;133:1478-80.
4. Rahimy E, Kuehlewein L, Sadda SR, Sarraf D. Paracentral Acute Middle Maculopathy: What We Knew Then and What We Know Now. *Retina* 2015;35:1921-30.
5. Khatibi A. Brazilian Booty Retinopathy: Purtscher-Like Retinopathy with Paracentral Acute Middle Maculopathy Associated with Pmma Injection into Buttocks. *Retin Cases Brief Rep* 2016.
6. Shahlaee A, Sridhar J, Rahimy E, Shieh WS, Ho AC. Paracentral Acute Middle Maculopathy Associated with Postviral Purtscher-Like Retinopathy. *Retin Cases Brief Rep* 2017.

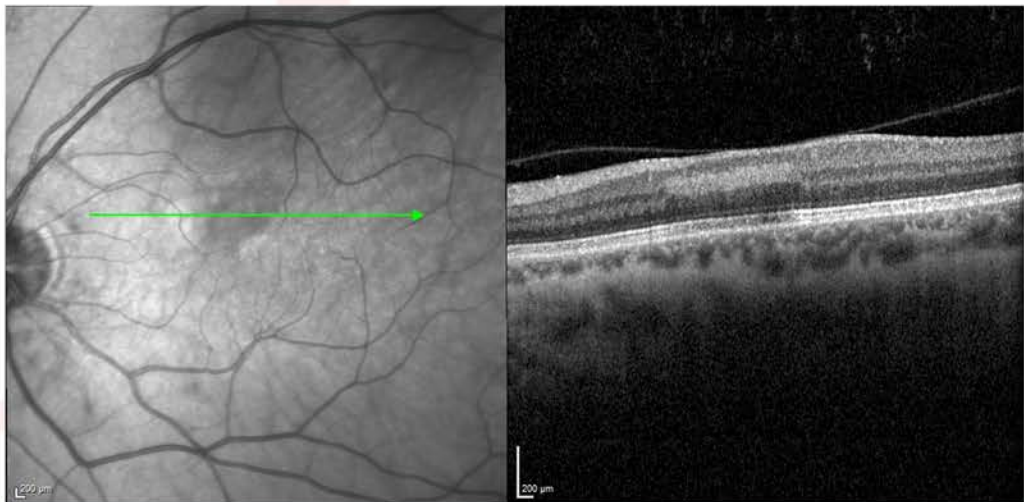
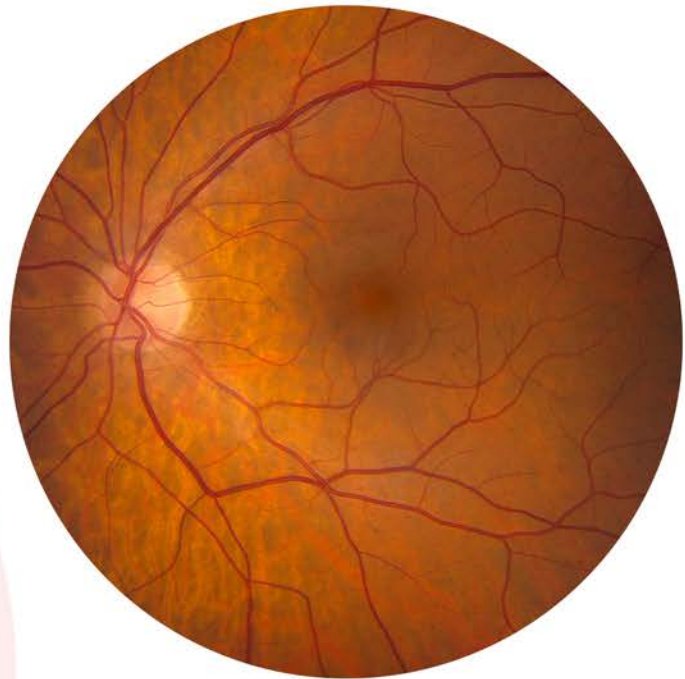

Figure 5: At the two-week follow up, fundus photo and OCT reveal near resolution of retinal whitening and hyper-reflectivity of middle retinal layers.

Want to see past issues  
of the Case of the Month?  
Visit our website at [tri-stl.com](http://tri-stl.com)

Case of the Month  
Supported by:

